

# Correlates of EMDR Therapy in Functional and Structural Neuroimaging: A Critical Summary of Recent Findings

**Marco Pagani**

*Institute of Cognitive Sciences and Technologies, CNR, Rome, Italy*

**Göran Högberg**

*Department of Clinical Neuroscience, Section for Psychiatry, Huddinge, Karolinska Institutet, Stockholm, Sweden*

**Isabel Fernandez**

*EMDR Italy Association, Bovisio Masciago (MI), Italy*

**Alberto Siracusano**

*Department of Systems Medicine, University of Rome "Tor Vergata," Rome, Italy*

Neuroimaging investigations of the effects of psychotherapies treating posttraumatic stress disorder (PTSD), including eye movement desensitization and reprocessing (EMDR), have reported findings consistent with modifications in cerebral blood flow (CBF; single photon emission computed tomography [SPECT]), in neuronal volume and density (magnetic resonance imaging [MRI]), and more recently in brain electric signal (electroencephalography [EEG]). Additionally in the recent past, EMDR-related neurobiological changes were monitored by EEG during therapy itself and showed a shift of the maximal activation from emotional limbic to cortical cognitive brain regions. This was the first time in which neurobiological changes occurring during any psychotherapy session have been reported, making EMDR the first psychotherapy with a proven neurobiological effect. The purpose of this article was to review the results of functional and structural changes taking place at PTSD treatment and presented during the period of 1999–2012 by various research groups. The reported pathophysiological changes are presented by neuropsychological technique and implemented methodology and critically analyzed.

**Keywords:** EMDR; neurobiology; EEG; SPECT; MRI; limbic system

**N**oninvasive brain activity recording techniques fall into two broad categories. The first are electromagnetic techniques: electroencephalography (EEG), event-related potential (ERP), and magnetoencephalography. These have excellent temporal resolution (a few milliseconds) but are coupled with poor spatial resolution (several centimeters). The second are hemodynamic- and metabolism-related techniques: functional magnetic resonance imaging (fMRI), single photon emission computed tomography (SPECT), positron emission tomography (PET), and near-infrared spectroscopy (NIRS). These measure regional cerebral blood flow (rCBF) and metabolic changes as an indicator of neural activity and are suitable for reliably investigating deep-brain areas. In addition, in contrast

to electromagnetic techniques, the latter have a good spatial resolution (1–6 mm) but poor temporal resolution (several seconds for fMRI and in the order of minutes for PET/CT; Plailly, Demarquay, & Royet, 2009).

The low temporal resolution is a clear disadvantage for the PET/CT and fMRI techniques when compared to that of electromagnetic techniques, which can monitor neural activity and identify changes occurring almost in real time. On the other hand, the better spatial resolution of the PET/CT and fMRI techniques makes them particularly useful for revealing both small clusters of activation as well as large-scale distributed networks including both cortical and deep-brain structures (Cabeza & Nyberg, 2000).

## Neuroimaging in Posttraumatic Stress Disorder

Noninvasive brain activity recording techniques have been used to study the anatomical and functional changes in individuals with posttraumatic stress disorder (PTSD). Functional (SPECT, PET, and fMRI) and structural (MRI) studies have shown significant neurobiological alterations in patients with PTSD during exposure to autobiographical script-driven imagery of trauma (Bremner, 2007). These studies led to the identification of metabolic and morphological changes in the brain, which occur when the disease becomes symptomatic and provided information about the role of each specific area in the complex mechanisms involved with the processing of emotions and psychological trauma. (For an extensive review, see Bremner, 2007.)

In PTSD changes (both increases and decreases) in blood flow, metabolism and volume of gray matter have been reported in the hippocampus, amygdala, medial prefrontal cortex, anterior and posterior cingulate, and temporal cortex (see a review by Francati, Vermetten, & Bremner, 2007). All these regions belong to the limbic system particularly involved in processing both positive and negative emotions. When the findings of these studies are combined, they unequivocally show in patients following traumatic events a pathological processing of traumatic memories associated with a correspondingly reduced medial prefrontal cortex and anterior cingulate control over a hyperreactive amygdala thought to be the core functional mechanisms implicated in PTSD.

The purpose of this article is double-fold: (a) to present and briefly discuss the available articles (indexed in PubMed 1999–2012) in which the neurobiological effects of various psychotherapies have been investigated by neuroimaging techniques and (b) focus on the advancements in neuroimaging research on eye movement desensitization and reprocessing (EMDR) and critically present the most recent results.

## Neuroimaging in Posttraumatic Stress Disorder Psychotherapies

Neuroimaging techniques have been used in an attempt to shed light on the functional and anatomical correlates of various psychotherapies revealing their neurobiological effects. In an extensive review, Roffman, Marci, Glick, Dougherty, and Rauch (2005) analyzed 14 functional neuroimaging investigations measuring the effects of psychotherapies on brain function. Despite the positive clinical outcome and sensible effects of behavioral, cognitive behavioral,

and interpersonal therapies on brain functions, the neuroanatomical changes were inconsistent both within disorders and within psychotherapies preventing any well-structured conclusion. However, the reviewed studies were conducted using various methodologies, experimental paradigms, and psychotherapies but more importantly on patient groups belonging to the whole spectrum of psychiatric diagnoses spanning from major depression to phobias and schizophrenia. Such heterogeneities resulted in difficulties to suggest plausible and convergent physiological mechanisms for the investigated treatments. To avoid this, in this review, only articles in which psychotherapies were used to treat PTSD will be included. We will analyze the performed studies separating different techniques and psychotherapies.

## Magnetic Resonance Imaging

Focusing on PTSD, in 2005, Lindauer et al. reported the effect of brief eclectic therapy (BET) on hippocampal volume. This high-definition MRI study showed at baseline an overall smaller hippocampus in 18 patients as compared to 14 traumatized controls. In the 9 patients assigned to the treatment group, such volume was not modified by BET in the manually segmented investigated structures (hippocampus, amygdala, and parahippocampal gyrus) despite the positive effect of psychotherapy on PTSD symptoms (Lindauer et al., 2005). However, hippocampi were found to be smaller in patients than in traumatized controls—a finding often reproduced in PTSD research. The question whether this anatomical condition is a *trait* (present before the index traumas) or *state* (following the index trauma) characteristic has not been clarified yet. In addition, because of the lack of patients' follow-up, the study did not conclusively shed light on the effects of therapy on the subcortical structures. In fact, the relatively short time of therapy (4 months) and overall minimal time elapsed between the end of psychotherapy and the MRI might not have been long enough for producing detectable anatomical changes, possibly occurring after a longer period after successful treatment.

## Single Photon Emission Computed Tomography

In the following years, the same group, always using BET, investigated in 10 participants the cerebral blood flow (CBF) by SPECT and reported that after psychotherapy with positive clinical outcome, the activation found during the script listening at baseline significantly lowered in the middle frontal gyrus. Furthermore, treatment efficacy, as measured by

PTSD scores, correlated positively with CBF in temporal and frontal cortex (Lindauer et al., 2008). However, this study was performed with a low-resolution SPECT camera, and the statistical differences threshold was set at the liberal level of  $p < .01$  uncorrected for multiple comparisons at voxel level.

Previously, Peres et al. (2007) published a study on 16 patients with PTSD before and after exposure to cognitive restructuring therapy. The investigation was performed using a low statistical threshold ( $p < .001$  uncorrected for multiple comparisons) and reported after successful psychotherapy a higher activation in cortical (temporal, parietal, and prefrontal lobes) and subcortical (thalamus) regions in the left hemisphere during a script-driven provocation paradigm.

## Neuroimaging in EMDR

EMDR (Shapiro, 2001) has been recognized as an evidence-based method for the treatment of psychological trauma and other anxiety disorders (Ehlers et al., 2010), although its mode of action on neural circuits is far from being completely clarified. A putative mechanism behind EMDR efficacy hypothesizes that pathological memories are retained in amygdala synapses following an overpotentiation of the alpha-amino-3-hydroxy-5-methyl-4-isoxazole (AMPA) receptors. Such strengthening would prevent morbid memories to merge via anterior cingulate cortex into the cognitive memory trace and to be properly stored (for review, see Harper, Rasolkhani-Kaòhorn, & Drozd, 2009). In animals, low-frequency tetanic stimulation (one to five pulses per second [hertz]) caused in the amygdalae depotentiation of AMPA receptors proportional to the stimulation frequency, thus erasing the traumatic memories (Bender, Bender, Brasier, & Feldman, 2006; Hölscher, Anwyl, & Rowan, 1997). Such neuronal excitation resembles the one given by psychotherapists during EMDR sessions (about 2 Hz), and the fine positive neurobiological mechanism of therapy might be related to a decreased depolarization rate of limbic system synapses provoked by bilateral sensory stimulation. The emotional memories pathologically retained in the amygdala will then move to brain cortex and will be properly elaborated (Lin, Yeh, Lu, & Gean, 2003). At a macroscopic level, the recent findings of hyperactivation of parahippocampal gyrus and limbic cortices during EMDR therapy (Pagani et al., 2012) seem to support such a hypothesis and encourage further investigations on this fascinating matter.

A body of research has been carried out to evaluate EMDR effectiveness, and a large number of studies

are focused on investigating its neurobiological substrate despite difficulties arising from both time and spatial resolution of the selected techniques. The neurobiological ground of the effectiveness of EMDR in the treatment of PTSD had been supported by SPECT studies, which have shown that after comparing the brain activity before and after therapy, significant changes in blood flow occurred mainly in limbic areas and prefrontal cortex. Overall, the results of these studies indicate a posttreatment reversal of the prefrontal and limbic abnormalities, which were clearly recognized at pretreatment and are a frequent neuroimaging findings in patients with PTSD. In fact, in spite of the caveat due to SPECT's relatively low-spatial resolution, the increased blood flow at posttreatment in the middle and lateral frontal cortex may reflect a higher control over the amygdala and an increased stabilization of the pathological brain hyperactivation, resulting in a reduction of anxiety somatosensory symptoms. These findings are consistent with clinical improvements, including depression and general affective disorders, demonstrating that EMDR has a significant impact on brain functions and that the emergent post-EMDR pattern of brain activity is consistent with changes that may be mitigating posttraumatic and anxiety conditions.

## Single Photon Emission Computed Tomography

The first study in which SPECT was used in EMDR research dates 1999 when Levin et al. published a case report on a participant with PTSD. Upon recall of the traumatic event, SPECT showed a CBF increase after therapy in anterior cingulate and left frontal lobe. Unfortunately, the authors, despite extensively discussing the positive clinical and neuropsychological outcome following EMDR therapy, only mentioned the functional effects and the design of the SPECT study (a within-participant comparison). In fact, the results of SPECT examination are reported omitting information on the camera type and resolution and without giving any detail about the implemented methodology for image analysis and for statistical levels, if any. However, notwithstanding the previously mentioned limitations, the study paved the way to the following ones demonstrating the feasibility to investigate brain pathophysiology during trauma reliving.

In 2005, Lansing, Amen, Hanks, and Rudy investigated brain activation during the recall of the traumatic event in six psychologically traumatized police officers before and after EMDR therapy. They found a significant blood flow decrease after the disappearance of PTSD clinical and neuropsychological

signs in occipital, left parietal lobe, and posterior frontal lobes as well as a significantly increased perfusion in the left inferior frontal gyrus. The study was conducted with a high-resolution SPECT camera and with an acceptable statistical threshold, considering the low number of participants and the exploratory nature of the investigation. The most relevant results were after EMDR the parallel decrease in perfusion in regions hyperaroused during the symptomatic phase and the increased blood flow in the inferior frontal cortex. These findings indirectly confirmed at functional level the impact of EMDR on the neurobiology of PTSD reversing the reduced prefrontal cortex control over amygdalae.

Considering the few reports on such a potentially compelling issue—the changes occurring in the brain with psychotherapies in general and related symptom elimination—our research group has committed to contribute by investigating the neurobiological events occurring at functional and anatomical levels with EMDR therapy. The studies performed in this vein were part of a large research project on PTSD among Stockholm public transportation employees that experienced a “person under a train” accident or an assault at work (Högberg et al., 2007, 2008 [clinical studies]; Looi et al., 2008, 2009; Nardo et al., 2010 [MRI studies]; Pagani et al., 2005; Pagani et al., 2007; Nardo et al., 2011 [SPECT studies]). In all these investigations, the Structured Clinical Interview for *Diagnostic and Statistical Manual of Mental Disorders, Fourth Edition (DSM-IV)* Axis I Disorders (SCID-I; First, Gibbon, Spitzer, & Williams, 1997) formed the basis for clinical diagnosis. Furthermore, results from interview-based and self-rating scales constituted the ground for neuropsychological assessment.

The project was inspired by a meta-analysis of 61 outcome trials for PTSD in which patients were treated with pharmacological and psychological therapies such as behavioral therapy, EMDR, relaxation training, hypnotherapy, and dynamic therapy (Van Etten & Taylor, 1998). The study concluded that the best psychological therapies were cognitive behavioral therapy (CBT) and EMDR, and that these psychotherapies were more effective than drug therapy. Thirty-two percent of patients on drugs discontinued treatment against 14% of patients treated with psychological therapies. A further meta-analysis came to the conclusion that EMDR and exposure therapies had positive clinical outcome in the treatment of PTSD (Davidson & Parker, 2001); and Bradley, Green, Russ, Dutra, and Westen (2005) reported that in more than half of the patients who completed treatment with CBT or EMDR, overall symptoms improved. However, in

all such studies, patients were monitored for less than 12 months, and Bradley et al. pointed out the lack of long-term follow-up. This caveat was overcome by Högberg et al. (2008) reporting a positive outcome of EMDR therapy 3 years after the last session.

The preliminary results from Lansing et al. (2005) were confirmed in 2007 by Pagani et al. (2007) in the larger SPECT study that has so far investigated the CBF changes occurring following EMDR therapy. Fifteen patients were scanned before and after therapeutic intervention. To increase the reliability of the study and the robustness of the results, a control group of 22 nonsymptomatic participants who had suffered the same trauma as the patients was included in the study. This latter methodological caution is of the highest relevance because it minimizes the possible bias in the results due to psychological heterogeneity between the two groups. Furthermore, a very strict statistical threshold was applied (false discovery rate correction at both voxel and cluster level) accepting the risk of false negatives due to Type II statistical errors. When comparing the 11 treatment responders with the controls, the significant group difference found before EMDR disappeared after treatment. Furthermore, responders showed, after therapy, a significant CBF normalization in parieto-occipital, visual cortex and in the hippocampus and an increase in lateral prefrontal cortex.

Taken together, the results of the latter two studies indicate that the regional blood flow decreases after successful EMDR therapy were associated to the remission of symptoms such as flashbacks, intrusive stressing memories, hallucinations, and persistent trauma reliving at somatic level. On the other hand, EMDR normalized the capability to retrieve important aspects of the trauma and improved attention and sense of self. In addition, the activation of the prefrontal cortex, deputed to inhibit the limbic system in response to pathological stimuli that resemble the traumatic event, recovered its inhibitory role reducing amygdala hyperactivation and the relative cortical hyperarousal.

The most recent SPECT EMDR study to date was performed by Oh and Choi (2007) in two patients suffering from a psychological traffic trauma. The authors found after EMDR a cerebral perfusion increase in bilateral dorsolateral prefrontal cortex and a decreased in the temporal association cortex. In addition, the SPECT scans were compared to those of a nontraumatized control group and the findings were in line with the previous ones indicating a tracer uptake normalization following EMDR therapy. As for the first Levin study the significance of the results of



this investigation is affected by the extremely low numerosity of the patients sample as well as by relatively poor statistics ( $p < .01$ ). However, the study also confirmed the general neurobiological effect of EMDR with a trend of a restoration of the cortical control over the hyperaroused subcortical limbic structures.

## Magnetic Resonance Imaging and Functional Magnetic Resonance Imaging

Most recently, some studies implementing MRI and fMRI have also attempted to give an insight into EMDR neurobiology. In 2007, Letizia et al. reported a case of a patient with PTSD in which the hippocampi were manually delineated on high-resolution MRI scans. After 8 weeks of EMDR treatment, the patient no longer met the PTSD criteria as clinically assessed and showed a bilateral increase of hippocampal volumes. The authors concluded that the volumetric changes occurring in such relatively short time could have been caused by either neurogenesis or increased water and electrolyte content in the hippocampi but left the door open to the hypothesis that both psychotherapy and pharmacotherapy may induce alterations in gene expression and structural changes in the brain. The same group has recently performed with the same methodology a second study (Bossini et al., 2012) aiming at investigating the hippocampal volume in 10 patients with PTSD treated with EMDR. They found that after therapy, hippocampal volume grew by 6% again in association with improvement in PTSD symptoms. In this article, the authors made no speculations about the nature of such phenomenon believing that future studies, possibly using a larger cohort of traumatized participants as well as comparing the structural data to those of a control group, are needed to investigate the hypothesized functional mechanisms underlying these anatomical changes.

A structural MRI study, including the same group of patients as in Pagani et al. (2007), demonstrated a decreased gray matter density in various limbic regions of patients not responding to therapy with EMDR as compared to those for whom treatment resulted in the disappearance of symptoms (Nardo et al., 2010). In posterior cingulate, parahippocampal, and insular cortices lower gray matter concentrations were found to be related to PTSD and EMDR therapies. These regions are known to be implicated in processes such as integration, encoding, and retrieval of autobiographical and episodic memories; emotional processing (i.e., classical conditioning, cognitive appraisal, experience of feeling states); interoceptive awareness; and self-referential conscious experience. Responsiveness to

EMDR, which in part aims to ameliorate such symptomatology, was preliminarily correlated with the same structural substrates. The importance of this study, awarded the Francine Shapiro Award in 2011 by the European EMDR Association, lies in the fact that structural MRI was performed only once, and so it was a static representation of the neurobiology of the brain before EMDR therapy. The patients not responding to therapy were the ones in whom gray matter density was more severely impaired, and it was thought that this may have interfered with the effectiveness of EMDR therapy. As well as in Bossini et al. (2012) study, larger cohorts of patients are necessary to determine if such finding is related to a trait factor or if such decreased neuronal density was caused by the trauma's impact on patients' neurobiology.

In 2009, Richardson et al. recorded the blood oxygenation signal during an EMDR session self-administered by a trained therapist in the magnetic camera gantry and found, compared to the resting state, a marked change in brain activation within the prefrontal cortex demonstrating a ventromedial shift extending to several limbic regions. They speculated that the pattern of results was consistent with the hypothesis that the EMDR protocol (in particular alternating bilateral stimulation) recruits a large cortical network to ameliorate symptom severity of PTSD. However, beyond being a case report, the functional study was performed in a nonecological, unfriendly, and unnatural examination environment resulting in possible biases caused by the physical and psychological discomfort to patients during the experimental conditions (Mazard et al., 2002).

## Near-Infrared Spectroscopy

Ohtani, Matsuo, Kasai, Kato, and Kato (2009) using NIRS performed a pioneering study directly monitoring brain hemodynamic changes during the process of decreasing distress of trauma-related recall by EMDR. Using tasks patterned by EMDR procedures, they also examined the longitudinal treatment-related changes. Although the investigation was confined to the frontal cortex, because of the technique's limited potential, it was found that recall with eye movements is associated to a significant decrease in oxygenated hemoglobin concentration in the lateral prefrontal cortex as compared with recall without eye movements. Longitudinally, oxygenated hemoglobin concentration during recall significantly decreased, and this reduction was correlated with clinical improvement when posttreatment data were compared to pretreatment data. The results were not

likely to be ascribed to changes in the global circulatory system caused by autonomic arousal because there was no alteration in the heart rate upon trauma recall. The authors suggested that the effectiveness of EMDR in patients with PTSD might be associated with the reduction of lateral prefrontal cortex overactivation during trauma-related recall with eye movement. However, NIRS technique limits the functional analysis to a thin volume of tissue right below the skull surface, and most of the systems include few detectors covering only a small part of the cerebral cortex preventing a whole brain analysis.

## Electroencephalography

Efforts were also made to discover the impact of the bilateral stimulation component of EMDR therapy. In 2004, Lamprecht et al. investigated by EEG the event-related brain potentials before and after a treatment session using EMDR. The most interesting result was obtained for the ERP P3a (a component of time-locked signals) known to be associated with the engagement of attention and evaluation of novel events to prepare subsequent behavioral action. Only the patient group showed a significant attenuation of the ERP P3a in the posttreatment session, suggesting that clinical improvement might be related to changes in information processing associated to a reduced orienting to novel stimuli and reduced arousal level after treatment.

Harper et al. (2009) reported that EEG recordings of EMDR sessions showed that low brain stimulation invokes a large response from the memory areas. This response is at a frequency of about 1.5 Hz demonstrating that the frequency and power of waveforms induced by bilateral brain stimulation during EMDR therapy are similar to those of slow oscillations and delta waves of slow-wave sleep, particularly in frontopolar regions. They speculated that depotentiation of fear memory synapses in the amygdala disrupts the fear memory circuits. This mechanical change results in a beneficial perceptual change. It was also significant that the brain state established during EMDR was found to be similar to that of the memory editing system of slow-wave sleep.

In the same vein, Propper and colleagues (Propper & Christman, 2008; Propper, Pierce, Geisler, Christman, & Bellorado, 2007) examined in normal participants the effects of the eye movements used in EMDR on interhemispheric EEG coherence. They found a decreased gamma frequency coherence associated with 30 seconds of bilateral eye movements with eyes

open. The eye movement manipulation used in this study was found to facilitate episodic memory and resulted in decreased interhemispheric EEG coherence in anterior prefrontal cortex. The conclusion was that changing interhemispheric coherence in frontal areas, the eye movements used in EMDR foster consolidation of traumatic memories, thereby decreasing the memory intrusions found in this disorder.

On the other hand, the interhemispheric interaction hypothesis in EMDR therapy was questioned by Samara, Elzinga, Slagter, and Nieuwenhuis (2011) who showed that healthy participants recalled more emotional (but not neutral) words following the eye movement procedure than following the control procedure. However, in their experiment, EEG analyses indicated no evidence that the eye movements altered participants' interhemispheric coherence, or that improvements in recall were correlated with such changes in coherence. Their findings casted doubt on the interhemispheric interaction hypothesis and may have important implications for research on the neurobiological mechanism underlying EMDR.

## Electroencephalography Monitoring in EMDR

However, to date, none of these studies succeeded in investigating with an accurate time resolution the real-time brain neurons firing in response to the external stimuli induced by EMDR because the effects of therapy on brain activation/deactivation were only recorded before and after treatment. This has restricted the reported information to static conditions not describing the detailed dynamics of regional neuronal synchronization during EMDR sessions—an essential step in the comprehension of the mechanism underlying EMDR therapy. One of the tools that might potentially help to overcome the limiting methodological factors is the EEG because it has a time resolution of milliseconds plus an acceptable capability to identify sources of activity within the brain's three-dimensional space.

Investigating by EEG the functional response before, during, and after EMDR therapy, Pagani et al. (2012) have recently broken fresh ground ever in disclosing real-time neuropathophysiological modifications relative to an EMDR treatment session for which a preliminary report describing methodology and feasibility was previously published (Pagani et al., 2011). To enable the experiment to be as ecological and patient friendly as possible, treatment was provided and EEG recordings were made in a quiet office of a

private practitioner. Participants were 10 individuals with major psychic trauma who had been consecutively referred to four skilled EMDR therapists and 10 healthy nontraumatized controls who agreed to participate in the study. The therapists who are all distinguished members of the EMDR Italy Association, volunteered to participate in the study to ensure the best possible outcome of the therapy.

A comparison was made between the brain activation in the acute phase and that in the posttreatment phase for the traumatized individuals during both autobiographic script and the “live mode” EMDR session. Such neurobiological changes were also compared to those occurring in the healthy participants investigated under the same experimental conditions for two reasons: (a) to rule out the possibility that any activation found in patients would derive from the ocular movements per se and/or from the simple recall of an autobiographic memory and (b) to investigate the possible differences in neuronal activation between traumatized and nontraumatized individuals undergoing the same psychological stimulus.

Pagani et al. (2012) reported significant differences between the EEG of patients and nonsymptomatic controls both when listening to the script and during bilateral ocular stimulation. They detected in the former a significantly greater activity in the orbitofrontal cortex, particularly the left hemisphere. On the contrary, the nontraumatized controls showed in both cases a greater activation in large areas of the frontal, temporal, and parietal lobes, especially in the right hemisphere (see Figure 1).

The comparison between the EEG of patients during the EMDR at the first and last session showed a significantly greater activation during the latter in the temporo-occipital cortex mainly on the left side (Pagani et al., 2012). In patients after therapy, a significant decrease was also observed in fast alpha and gamma components of the activation present in the frontoparietal cortex at the first EMDR session (see Figure 2).

## General Discussion

The main objective of the reviewed series of anatomo-functional studies carried out in the last 13 years was to broaden our knowledge on the neurobiological ground underlying successful EMDR therapy. This has been pursued using various methodologies (neuropsychology, SPECT, MRI, and EEG) trying to disclose the neuronal changes on EMDR occurring within different aspects of human pathophysiology,

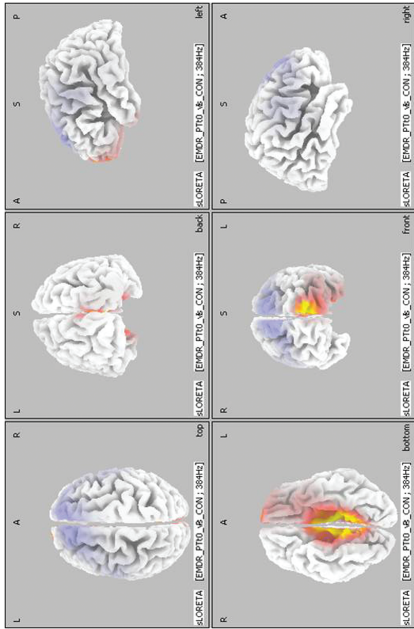
that is, neuropsychology, blood perfusion, neuronal density, and electrical activation. This exciting journey has led to confirming the initial sparse evidence of the association between the clinical outcome of EMDR therapy and some changes in brain functions and structures and has also confirmed the real-time monitoring feasibility of cortical activations during desensitization induced by ocular bilateral movements during EMDR therapy. This technical and scientific success has also allowed us to represent for the first time the dominant brain activations caused by the therapeutic actions mediated by an exposure therapy protocol. This has made EMDR the first psychotherapy with a proven neurobiological effect.

During the phases of script listening across most of the reviewed studies, a concordant cortical activation in limbic areas was found at the stage in which the effects of trauma are clinically evident. The predominant activation of these regions in the symptomatic phase can be explained as an emotional hyperarousal during the trauma reliving and is considered to represent the neurobiological correlate of the affective valence of the stimulus (Steele & Lawrie, 2004). The study of Pagani et al. (2012) confirmed the same trend also during the phase of bilateral ocular stimulation of initial EMDR therapy.

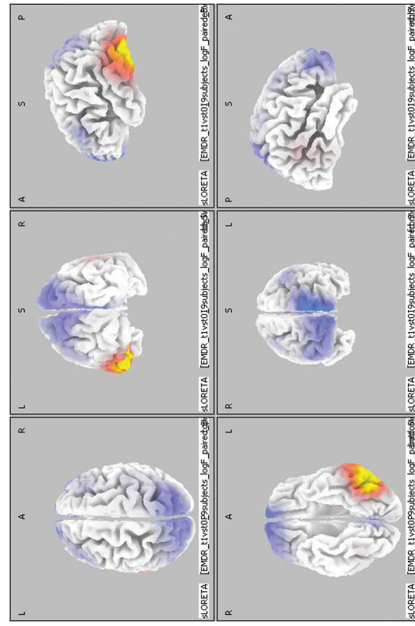
The significant normalization of these activations after the trauma processing can be interpreted as the neurobiological correlate of clinical recovery. This speaks in favor of a shift of emotive attention to cortical regions with a dominant cognitive and sensorial role. Hence the memory retention of the traumatic event can move from an implicit subcortical to an explicit cortical status where different regions participate in processing the experience. This is also likely to be related to a previously reported effect of EMDR on short-term memory in the processing of which primarily associative areas are activated (van den Hout et al., 2011).

Critically comparing the findings of the recent EEG study (Pagani et al., 2012) with previous CBF SPECT investigation (Lansing et al., 2005; Pagani et al., 2007), it was found that the same brain regions are implicated in the response to EMDR therapy (Figure 3). This cross-validates the two methodologies and implicates that EMDR therapy is associated with functional changes in the same topographic regions as those activated by the autobiographical script (i.e., fusiform gyri and occipital and frontal cortex) confirming its potency across different studies and completely different groups of patients and traumatic events.

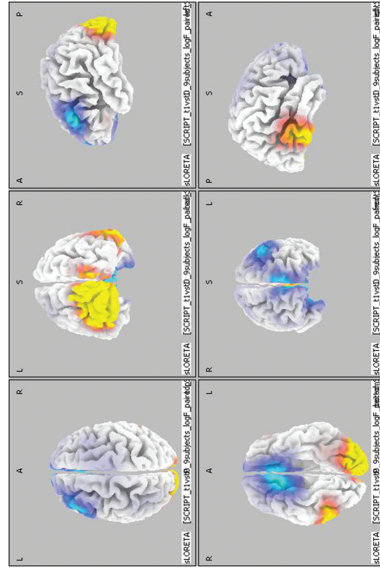
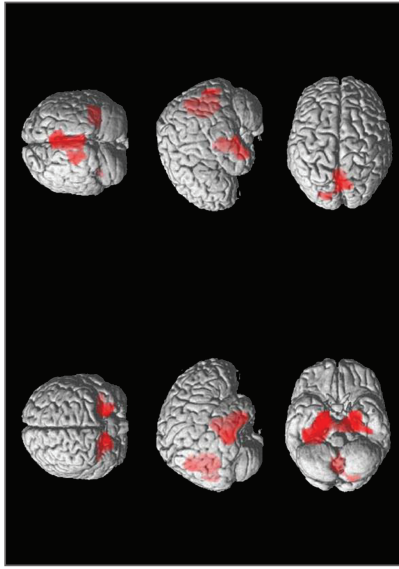




**FIGURE 1.** Patients during the first eye movement desensitization and reprocessing (EMDR) session versus normal controls: Cortical representation of the cluster of voxels in which the electroencephalography (EEG) signal during EMDR showed significant differences. Activation increases and decreases exceeding a  $p$  value  $< .01$  and an  $F$  value over 2  $z$  score are depicted by red and blue color scale, respectively. Top row left: view from above; top row middle: posterior view; top row right: lateral view of the left hemisphere; bottom row left: view from below; bottom row middle: frontal view; bottom row right: lateral view of the right hemisphere.



**FIGURE 2.** Patients during the first eye movement desensitization and reprocessing (EMDR) session versus patients during the last EMDR session: Cortical representation of the cluster of voxels in which the electroencephalography (EEG) signal showed significant differences. Activation increases and decreases exceeding a  $p$  value  $< .01$  and an  $F$  value over 2  $z$  score are depicted by red and blue color scale, respectively. Top row left: view from above; top row middle: posterior view; top row right: lateral view of the left hemisphere; bottom row left: view from below; bottom row middle: frontal view; bottom row right: lateral view of right hemisphere.



**FIGURE 3.** Post-eye movement desensitization and reprocessing (EMDR) versus pre-EMDR brain functional differences during autobiographical script listening: Cortical representation of the cluster of voxels showing significant differences in single photon emission computed tomography (SPECT) and electroencephalography (EEG) images. SPECT (in red): the regions in which perfusion at SPECT was increased after therapy. Top image, top row left: frontal view; top row right: posterior view; middle row right: lateral view of the right hemisphere; middle row left: lateral view of the right hemisphere; bottom row left: view from below; bottom row right: view from above. EEG: In red scale: the regions in which EEG signal was increased after therapy. Bottom image, top row left: view from above; top row middle: posterior view; top row right: lateral view of the left hemisphere; bottom row left: view from below; bottom row middle: frontal view; bottom row right: lateral view of right hemisphere.



## Conclusions

In conclusion, during the last decade, functional and anatomical studies have yielded very promising results supporting the evidence of neurobiological models explaining the changes following EMDR therapy as well as describing cortical activations specific for script listening and bilateral ocular desensitization. These findings stimulate the continuation of the efforts to unravel the pathophysiological mechanisms underlying this highly effective treatment of PTSD.

## References

- Bender, V. A., Bender, K. J., Brasier, D. J., & Feldman, D. E. (2006). Two coincidence detectors for spike timing in somatosensory cortex. *Journal of Neuroscience*, *26*, 4166–4177.
- Bossini, L., Casolaro, I., Santarnecchi, E., Caterini, C., Koukouna, D., Fernandez, I., & Fagiolini, A. (2012). Evaluation study of clinical and neurobiological efficacy of EMDR in patients suffering from post-traumatic stress disorder. *Rivista di Psichiatria*, *47*(2 Suppl.), 12–15.
- Bradley, R., Green, J., Russ, E., Dutral, L., & Westen, D. (2005). A multidimensional meta-analysis of psychotherapy for PTSD. *American Journal of Psychiatry*, *162*, 214–227.
- Bremner, J. D. (2007). Functional neuroimaging in post-traumatic stress disorder. *Expert Review of Neurotherapeutics*, *7*, 393–405.
- Cabeza, R., & Nyberg, L. (2000). Imaging cognition II: An empirical review of 275 PET and fMRI studies. *Journal of Cognitive Neuroscience*, *12*(1), 1–47.
- Davidson, P. R., & Parker, K. C. H. (2001). Eye movement desensitization and reprocessing (EMDR): A meta-analysis. *Journal of Consultant Clinical Psychology*, *69*, 305–316.
- Ehlers, A., Bisson, J., Clark, D. M., Creamer, M., Pilling, S., Richards, D., . . . Yule, W. (2010). Do all psychological treatments really work the same in posttraumatic stress disorder? *Clinical Psychology Review*, *30*, 269–276.
- First, M. B., Gibbon, M., Spitzer, R. L., & Williams, J. B. W. (1997). *Structured Clinical Interview for DSM-IV Axis I Disorders (SCID-I)*. Clinician booklet. Washington, DC: American Psychiatric Association.
- Francati, V., Vermetten, E., & Bremner, J. D. (2007). Functional neuroimaging studies in posttraumatic stress disorder: Review of current methods and findings. *Depression and Anxiety*, *24*, 202–218.
- Harper, M. L., Rasolkhani-Kaohorn, T., & Drozd, J. F. (2009). On theneural basis of EMDR therapy: Insights from qEEG studies. *Traumatology*, *15*, 81–95.
- Högberg, G., Pagani, M., Sundin, O., Soares, J., Aberg-Wistedt, A., Tärnell, B., & Hällström, T. (2007). On treatment with eye movement desensitization and reprocessing of chronic post-traumatic stress disorder in public transportation workers—a randomized controlled trial. *Nordic Journal of Psychiatry*, *61*, 54–61.
- Högberg, G., Pagani, M., Sundin, O., Soares, J., Aberg-Wistedt, A., Tärnell, B., & Hällström, T. (2008). Treatment of post-traumatic stress disorder with eye movement desensitization and reprocessing: Outcome is stable in 35-month follow-up. *Psychiatry Research*, *59*, 101–108.
- Hölscher, C., Anwyl, R., & Rowan, M. J. (1997). Stimulation on rhythm long- depotentiated by stimulation on the negative phase in area CA1 in vivo. *Journal of Neuroscience*, *17*, 6470–6477.
- Lamprecht, F., Köhnke, C., Lempa, W., Sack, M., Matzke, M., & Münte, T. F. (2004). Event-related potentials and EMDR treatment of post-traumatic stress disorder. *Neuroscience Research*, *49*, 267–272.
- Lansing, K., Amen, D. G., Hanks, C., & Rudy, L. (2005). High-resolution brain SPECT imaging and eye movement desensitization and reprocessing in police officers with PTSD. *Journal of Neuropsychiatry and Clinical Neuroscience*, *17*, 526–532.
- Letizia, B., Andrea, F., & Paolo, C. (2007). Neuroanatomical changes after eye movement desensitization and reprocessing (EMDR) treatment in posttraumatic stress disorder. *Journal of Neuropsychiatry and Clinical Neurosciences*, *19*, 475–476.
- Levin, P., Lazrove, S., & van der Kolk, B. (1999). What psychological testing and neuroimaging tell us about the treatment of posttraumatic stress disorder by eye movement desensitization and reprocessing. *Journal of Anxiety Disorders*, *13*, 159–172.
- Lin, C. H., Yeh, S. H., Lu, H. Y., & Gean, P. W. (2003). The similarities and diversities of signal pathways leading to consolidation of conditioning and consolidation of extinction of fear memory. *Journal of Neuroscience*, *23*, 8310–8317.
- Lindauer, R. J., Booij, J., Habraken, J. B., van Meijel, E. P., Uylings, H. B., Olff, M., . . . Gersons, B. P. (2008). Effects of psychotherapy on regional cerebral blood flow during trauma imagery in patients with post-traumatic stress disorder: A randomized clinical trial. *Psychological Medicine*, *38*, 543–554.
- Lindauer, R. J., Vlieger, E. J., Jalink, M., Olff, M., Carlier, I. V., Majoie C. B., . . . Gersons, B. P. (2005). Effects of psychotherapy on hippocampal volume in out-patients with post-traumatic stress disorder: A MRI investigation. *Psychological Medicine*, *35*, 1421–1431.
- Looi, J. C., Lindberg, O., Liberg, B., Tatham, V., Kumar, R., Maller, J., . . . Wahlund, L. O. (2008). Volumetrics of the caudate nucleus: Reliability and validity of a new manual tracing protocol. *Psychiatry Research*, *163*, 279–288.
- Looi, J. C., Maller, J. J., Pagani, M., Högberg, G., Lindberg, O., Liberg, B., . . . Wahlund, L. O. (2009). Caudate volumes in public transportation workers exposed

- to trauma in the Stockholm train system. *Psychiatry Research*, 171, 138–143.
- Mazard, A., Mazoyer, B., Etard, O., Tzourio-Mazoyer, N., Kosslyn, S. M., & Mellet, E. (2002). Impact of fMRI acoustic noise on the functional anatomy of visual mental imagery. *Journal of Cognitive Neuroscience*, 14, 172–186.
- Nardo, D., Högberg, G., Flumeri, F., Jacobsson, H., Larsson, S. A., Hällström, T., & Pagani, M. (2011). Self-rating scales assessing subjective well-being and distress correlate with rCBF in PTSD-sensitive regions. *Psychological Medicine*, 41, 2549–2561.
- Nardo, D., Högberg, G., Looi, J., Larsson, S. A., Hällström, T., & Pagani, M. (2010). Grey matter changes in posterior cingulate and limbic cortex in PTSD are associated with trauma load and EMDR outcome. *Journal of Psychiatry Research*, 44, 477–485.
- Oh, D. H., & Choi, J. (2007). Changes in the cerebral perfusion after EMDR. *Journal of EMDR Practice and Research*, 1, 24–30.
- Ohtani, T., Matsuo, K., Kasai, K., Kato, T., & Kato, N. (2009). Hemodynamic responses of eye movement desensitization and reprocessing in posttraumatic stress disorder. *Neuroscience Research*, 65, 375–383.
- Pagani, M., Di Lorenzo, G., Verardo, A. R., Nicolais, G., Monaco, L., Lauretti, G., . . . Fernandez, I. (2011). Preintra- and post-treatment EEG imaging of EMDR—Methodology and preliminary results from a single case. *Journal of EMDR Practice and Research*, 5, 42–56.
- Pagani, M., Di Lorenzo, G., Verardo, A. R., Nicolais, G., Monaco, L., Lauretti, G., . . . Fernandez, I. (2012). Neurobiology of EMDR—EEG imaging of treatment efficacy. *PLoS One*, 7, e45753.
- Pagani, M., Högberg, G., Salmaso, D., Nardo, D., Tärnell, B., Jonsson, C., . . . Sundin, Ö. (2007). Effects of EMDR psychotherapy on 99mTc-HMPAO distribution in occupation-related post-traumatic stress disorder. *Nuclear Medicine Communications*, 28, 757–765.
- Pagani, M., Högberg, G., Salmaso, D., Tärnell, B., Sanchez-Crespo, A., Soares, J., . . . Sundin, O. (2005). Regional cerebral blood flow during auditory recall in 47 subjects exposed to assaultive and non-assaultive trauma and developing or not posttraumatic stress disorder. *European Archives of Psychiatry and Clinical Neuroscience*, 255, 359–365.
- Peres, J. F., Newberg, A. B., Mercante, J. P., Simão, M., Albuquerque, V. E., Peres, M. J., & Nasello, A. G. (2007). Cerebral blood flow changes during retrieval of traumatic memories before and after psychotherapy: A SPECT study. *Psychological Medicine*, 37, 1481–1491.
- Plailly, J., Demarquay, G., & Royet, J. P. (2009). Cerebral imaging and olfactory disorders: A review. *B-ENT*, (5 Suppl. 13), 61–69.
- Propper, R. E., & Christman, S. D. (2008). Interhemispheric interaction and saccadic horizontal eye movements: Implications for episodic memory, EMDR, and PTSD. *Journal of EMDR Practice and Research*, 2(4), 269–281.
- Propper, R. E., Pierce, J., Geisler, M. W., Christman, S. D., & Bellorardo, N. (2007). Effect of bilateral eye movements on frontal interhemispheric gamma EEG coherence: Implications for EMDR therapy. *Journal of Nervous Mental Disorders*, 195, 785–788.
- Richardson, P., Williams, S. R., Hepenstall, S., Gregory, L., McKie, S., & Corrigan, F. (2009). EMDR treatment of a patient with posttraumatic stress disorder. *Journal of EMDR Practice and Research*, 3, 10–23.
- Roffman, J. L., Marci, C. D., Glick, D. M., Dougherty, D. D., & Rauch, S. L. (2005). Neuroimaging and the functional neuroanatomy of psychotherapy. *Psychological Medicine*, 35, 1385–1398.
- Samara, Z., Elzinga, B. M., Slagter, H. A., & Nieuwenhuis, S. (2011). Do horizontal saccadic eye movements increase interhemispheric coherence? Investigation of a hypothesized neural mechanism underlying EMDR. *Frontiers in Psychiatry*, 2, 4.
- Shapiro, F. (2001). *Eye movement desensitization and reprocessing: Basic Principles, protocols, and procedure* (2nd ed.). New York, NY: Guilford Press.
- Steele, J. D., & Lawrie, S. M. (2004). Segregation of cognitive and emotional function in the prefrontal cortex: A stereotactic meta-analysis. *Neuroimage*, 21, 868–875.
- Van den Hout, M. A., Engelhard, I. M., Rijkeboer, M. M., Koekebakker, J., Hornsveld, H., Leer, A., . . . Akse, N. (2011). EMDR: Eye movements superior to beeps in taxing working memory and reducing vividness of recollections. *Behavioral Research and Therapy*, 49, 92–98.
- Van Etten, M. L., & Taylor, S. (1998). Comparative efficacy of treatments for post-traumatic stress disorder: A meta-analysis. *Clinical Psychology and Psychotherapy*, 5, 126–144.

**Acknowledgements.** The authors wish to thank Mrs. Emanuela Enrico for assisting in English editing.

Correspondence regarding this article should be directed to Marco Pagani, Institute of Cognitive Sciences and Technologies, CNR, Via Palestro 32, 00185, Rome, Italy. E-mail: marco.pagani@istc.cnr.it